

Procedure and timing for carotid endarterectomy for carotid stenosis: Review

Haitham Salih O Alsammahy, Bassam Awad M Alzubaidi, Nasser Abdullah N Aldawsari,
Sultan Thayer N Alharbi

Abstract

In this review we discuss carotid endarterectomy, focusing on mainly its timing and procedure technique. We conducted computerized search among electronic databases; MEDLINE, EMBASE, and SciELO for literature available in the databases to October, 2017. Carotid endarterectomy is a surgical procedure used to reduce the risk of stroke by correcting stenosis in the common carotid artery or internal carotid artery. The procedure requires careful diagnosis and preparation. Selection of proper timing is crucially important in order to reduce the postoperative complications and gain a well functioning artery.

Introduction

Stroke is the third leading cause of death in the United States, and the second leading cause of death worldwide [1]. It is the most common cause of death as a result of a neurological disorder. About 750,000 patients are diagnosed with this entity yearly in the United States and more than 15 million around the globe, which corresponds to an incidence of new stroke of approximately 160 per 100,000 population per year [2].

The aim of carotid endarterectomy is to reduce the risk of stroke and death in patients with carotid artery disease. The benefit to society of surgeons undertaking this operation lies in the balance between the risks of the natural history of the carotid disease and the risks of the

surgical treatment. Carotid endarterectomy is probably the vascular surgical procedure with the most scientific evidence in its favour [3].

The natural history of carotid disease is quite different for patients with symptomatic and asymptomatic carotid arterial stenoses. Symptomatic stenoses include those causing transient ischaemic attack and amaurosis fugax. Also included are patients who have had a previous completed stroke [4]. Asymptomatic patients may have a significant carotid stenosis found incidentally, they may have a moderate stenosis that progresses on duplex follow-up, or finally they may have a stenosis identified as part of a routine preoperative work-up before major surgery such as coronary artery bypass grafting [5].

Patients with no significant carotid disease have a less than 2% chance of perioperative stroke during and after coronary artery bypass, whereas patients with a unilateral occlusion have an approximately 10% chance. However, only 40% of these strokes occur within 24 hours of surgery and are thus likely to be preventable [6].

The endarterectomy procedure was developed and first done by the Portuguese surgeon Joao Cid dos Santos in 1946, when he operated an occluded superficial femoral artery, at the University of Lisbon. In 1951 an Argentinian surgeon repaired a carotid artery occlusion using a bypass procedure. The first endarterectomy was successfully performed by Michael DeBakey around 1953, at the Methodist Hospital in Houston, TX, although the technique was not reported in the medical literature until 1975 [7]. The first case to be recorded in the medical literature was in The Lancet in 1954; the surgeon was Felix Eastcott, a consultant surgeon and deputy director of the surgical unit at St Mary's Hospital, London, UK [8]. Eastcott's procedure was not strictly an endarterectomy as we now understand it; he excised the diseased part of the artery and then resutured the healthy ends together [9].

Methodology:

We performed an electronic search of MEDLINE, EMBASE, and SciELO databases. These databases were searched for eligible studies discussing the carotid endarterectomy for carotid stenosis. Our search had no limit period of studies publication, therefore, we searched through October, 2017 Relevant references and historical quotes, as well as extremely important studies within the context of the review were analyzed in the same way, regardless of the publication dates.

Discussion

· Diagnostic procedures:

Brain imaging with CT or MRI should be obtained in patients considered for CEA, in order to document infarction and rule out mass lesions. Carotid investigation begins with ultrasound and, if results agree with subsequent, good-quality MRA or CT angiography (Figure 1), treatment can be planned and catheter angiography avoided. An equally acceptable approach is to proceed directly from ultrasound to catheter angiography, which is still the gold-standard in carotid artery assessment [10].

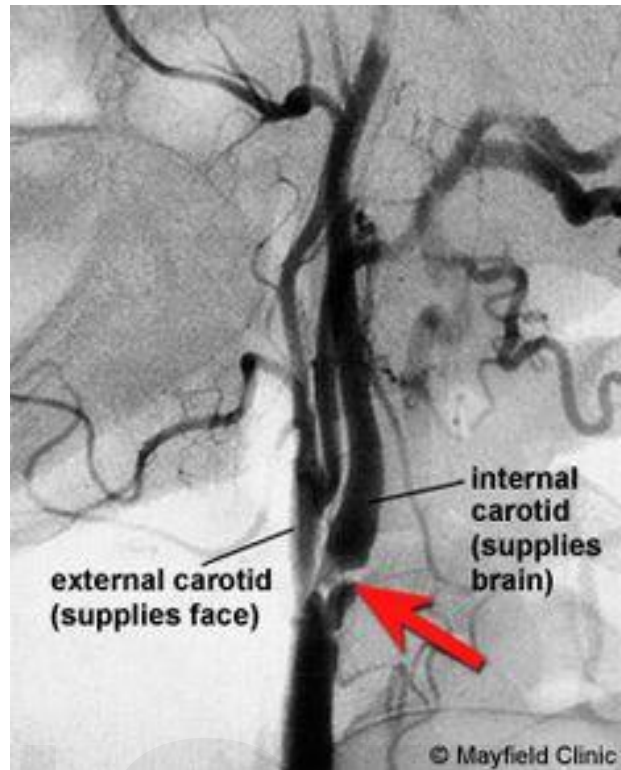


Figure 1: Carotid stenosis

Source: <https://hu.pinterest.com/pin/502995852109250901/>

- **Indications of surgery:**

CEA should be considered for any patient with carotid artery stenosis in whom surgery will improve the natural history of the disease to a greater degree than the corresponding medical treatment would [11].

In symptomatic good-risk patients with surgical morbidity and mortality (stroke and death) of less than 6%, proven indications for CEA include the following:

- One or more transient ischemic attacks (TIAs) in the preceding 6 months and carotid artery stenosis exceeding 50% [12].

In asymptomatic good-risk patients treated by surgeons with surgical mortality and morbidity of less than 3%, the proven indication for CEA is stenosis exceeding 60% [13].

The 2014 American Heart Association (AHA)/American Stroke Association (ASA) guidelines for the prevention of stroke in patients with stroke or TIA contained the following new or updated recommendations relevant to CEA [14]:

- Carotid angioplasty and stenting (CAS) is indicated as an alternative to CEA for symptomatic patients at average or low risk for complications associated with endovascular intervention when the diameter of the lumen of the internal carotid artery is reduced by >70% by noninvasive imaging or >50% by catheter-based imaging or noninvasive imaging with corroboration and the anticipated rate of periprocedural stroke or death is <6% (class IIa; evidence level B)
- It is reasonable to consider patient age in choosing between CAS and CEA; for patients older than about 70 years, CEA may be associated with improved outcome CAS, particularly when the arterial anatomy does not favor endovascular intervention; for younger patients, CAS is equivalent to CEA in terms of risk for periprocedural complications and long-term risk for ipsilateral stroke (class IIa; evidence level B)
- CAS and CEA in the above settings should be performed by operators with established periprocedural stroke and mortality rates of < 6% for symptomatic patients (class I; evidence level B)
- Routine, long term follow-up imaging of the extracranial carotid circulation with carotid duplex ultrasonography is not recommended (class III; evidence level B)

Contraindications

CEA is contraindicated if the patient's general condition includes a serious illness that will substantially increase perioperative risk or shorten life expectancy. It is also contraindicated in

patients who present acutely with a major stroke or in patients who experienced a major devastating stroke with minimal recovery or a significantly altered level of consciousness [15]. In a study of perioperative and long-term outcomes after CEA in hemodialysis patients, Cooper et al found that the risks of CEA in asymptomatic dialysis-dependent patients were high, possibly outweighing the benefits. They also found the risk to be high in symptomatic patients and suggested that it should be offered only to a small and carefully selected cohort of these patients [16].

Timing

Contemporary literature argues that neurologically unstable patients, presenting repetitive transient ischaemic attacks or progressing stroke, should be managed by urgent (within 24 to 72 hours) carotid endarterectomy, even if the peri-operative stroke-death rate is slightly higher than in the elective setting. Despite an inherent increased operative morbidity-mortality, urgent carotid endarterectomy seems to be justified by the fact that waiting for the surgery may lead to the development of a more profound stroke in these neurologically unstable patients. Their only chance for neurological recovery (partial or complete) is in the early phase (12 to 60 hours after the acute onset of the neurological syndrome of crescendo-TIAs or stroke-in-evolution). For patients presenting a minor stroke, with limited brain infarction, carotid endarterectomy should preferentially be done in a semi-urgent fashion, within two weeks [17].

Preoperative assessment

In the preoperative work-up of a patient, it is important to consider if the patient is at “physiological” high risk for surgery, which may warrant consideration for other alternatives such as carotid artery stenting or medical management. These factors include, but are not restricted to, advanced age, contralateral carotid occlusion, cardiac disease, and renal insufficiency [18].

It is of utmost importance in the evaluation of the patient who has recently suffered a stroke and has not recovered completely to assess whether he or she is a candidate for surgery. This requires considerable experience and judgment. It has been suggested that patients should wait 4–6 weeks after the event prior to proceeding with CEA [19] [20]. However, the patient may be at high risk of a recurrent neurologic event during that period [21]. After an ischemic event, the 30-day risk of stroke is 4.9% in the presence of severe carotid stenosis [22]. On the other hand, the mortality and risk of stroke at CEA is 20% in the presence of stroke in evolution or crescendo TIA [23].

Particular steps in the preoperative management of patients planning to undergo CEA include the appropriate antiplatelet medication. Aspirin therapy is continued in the perioperative period. Anticoagulation with heparin should be considered prior to CEA for high-grade stenosis and symptoms (acute stroke or crescendo TIA) to prevent another ischemic episode or complete arterial occlusion [24] [25].

Anatomical and technical considerations

The aortic arch provides the great vessels, including the innominate artery, the left common carotid artery (CCA), and the subclavian artery. (Figure 2) In the most common configuration, the innominate artery branches into the right subclavian artery and the right CCA. Vertebral arteries branch off the subclavian arteries bilaterally [26].

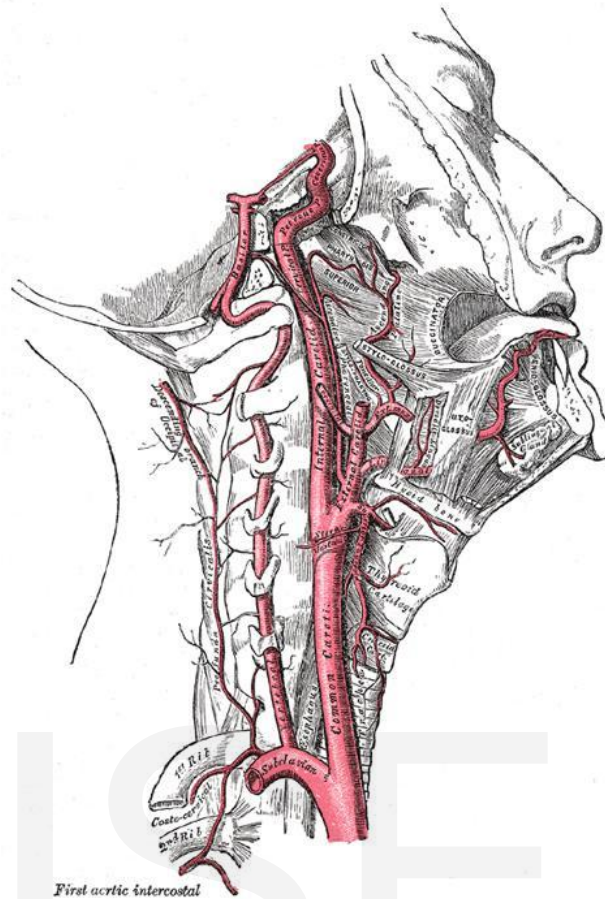


Figure 2: Anatomy of internal carotid and vertebral arteries
Source: <https://emedicine.medscape.com/article/1895291-overview#a5>

On each side, the CCA travels within the carotid sheath before branching into the ipsilateral internal carotid artery (ICA) and external carotid artery (ECA). The ECA primarily supplies blood to the face and includes branches of the superior thyroid and ascending pharyngeal arteries. The ICA has no extracranial branches [26].

The carotid sinus is a baroreceptor located at the carotid bifurcation (where the CCA bifurcates into the ICA and the ECA) and is innervated by the nerve of Hering, a branch from cranial nerve IX (the glossopharyngeal nerve). The carotid bifurcation also contains the carotid body, which functions as a chemoreceptor responding to low oxygen levels or high carbon dioxide levels [27].

The ICA has an intracranial branch called the ophthalmic artery, which collateralizes and communicates with the external carotid blood supply. The ophthalmic artery is a common location for carotid emboli, which may result in transient monocular blindness (TMB) if they dissolve quickly or central retinal artery occlusion and blindness if they do not. The intracranial circle of Willis provides further communication between the ICA, the ECA, and the vertebrobasilar system [28].

Operative techniques

Carotid endarterectomy (Figure 3) can be performed with either regional or general anaesthesia and, for the latter, there are a number of monitoring techniques available to assess cerebral perfusion during carotid cross-clamping. While monitoring cannot be considered mandatory and no single monitoring technique has emerged as being clearly superior, EEG is most commonly used. "Eversion" endarterectomy is a variation in surgical technique, and there is some evidence that more widely practiced patch closure may reduce the acute risk of operative stroke and the longer-term risk of recurrent stenosis [29].

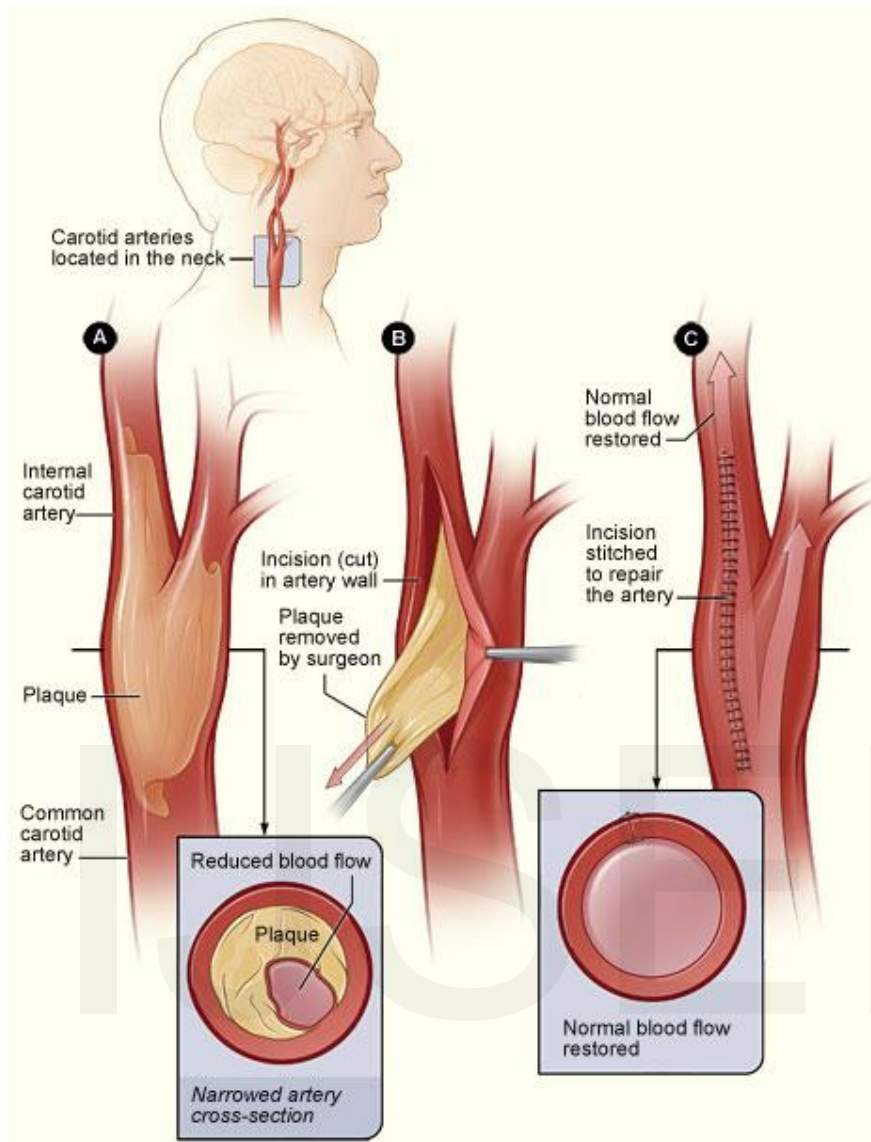


Figure 3: Carotid endarterectomy

Source: <https://hu.pinterest.com/pin/502995852109250901/>

The procedure of carotid endarterectomy consists of the following steps:

An incision is made on the midline side of the sternocleidomastoid muscle. The incision is between 5 and 10 cm in length. The internal, common and external carotid arteries are carefully identified, controlled with vessel loops, and clamped. The lumen of the internal carotid artery is opened, and the atheromatous plaque substance removed. The artery is closed using suture and a patch to increase the size of the lumen. Hemostasis is achieved, and the

overlying layers closed with suture. The skin can be closed with suture which may be visible or invisible (absorbable). Many surgeons place a temporary shunt to ensure blood supply to the brain during the procedure [30].

Once endarterectomy is performed, the surgeon is confronted with the choice of primary closure of the carotid artery or the use of a patch material. The traditional approach is to patch patients believed to be at high risk of recurrence, such as women and those with small carotid arteries [31].

The different materials available for patching include autologous vein graft, Dacron, ePTFE, and bovine pericardium. Surgeons may have their preference based on the malleability or other characteristics of the material [32]. Hence, at the present moment, there is no consensus that any particular type of patch material is better than the other. A possible disadvantage of vein patch is patch disruption, and that of prosthetic material is infection [33].

Carotid angioplasty and stenting:

Experience with this endovascular and less invasive procedure grows, and its technology continues to evolve. Some experienced therapists have reported excellent results in case series and a number of randomized trials are now underway comparing CAS to CEA [34]. CAS is cheaper, reduces hospital stay, avoids surgical complications and is more comfortable and tolerable for patients. However, at this time it is premature to incorporate CAS into routine practice replacing CEA [35].

Complications

For patients to benefit from revascularization, the surgeon's complication rate (30 day stroke and death) must remain $\leq 3\%$ for asymptomatic and $\leq 6\%$ of symptomatic patients. Other

surgical complications include hemorrhage of the wound bed, which is potentially life-threatening, as swelling of the neck due to hematoma could compress the trachea. Rarely, the hypoglossal nerve can be damaged during surgery. This is likely to result in fasciculations developing on the tongue and paralysis of the affected side: on sticking it out, the patient's tongue will deviate toward the affected side. Another rare but potentially serious complication is hyperperfusion syndrome because of the sudden increase in perfusion of the vasculature distal to stenosis [36].

Conclusion

Contemporary literature argues that neurologically unstable patients, presenting repetitive transient ischaemic attacks or progressing stroke, should be managed by urgent (within 24 to 72 hours) carotid endarterectomy, even if the peri-operative stroke-death rate is slightly higher than in the elective setting. Despite an inherent increased operative morbidity-mortality, urgent carotid endarterectomy seems to us justified by the fact that waiting for the surgery may lead to the development of a more profound stroke in these neurologically unstable patients. Their only chance for neurological recovery (partial or complete) is in the early phase (12 to 60 hours after the acute onset of the neurological syndrome of crescendo-TIAs or stroke-in-evolution). For patients presenting a minor stroke, with limited brain infarction, carotid endarterectomy should preferentially be done in a semi-urgent fashion, within two weeks.

References

1. World Health Organization (WHO). Surveillance in brief: Update of noncommunicable diseases and mental health surveillance activities. Issue No. 5 Geneva, WHO, 5:1–5, 2003.
2. Rothwell PM, Slattery J, Warlow CP. Clinical and angiographic predictors of stroke and death from carotid endarterectomy: systematic review. *BMJ*. 1997;315:1571-7.
3. Earnshaw JJ. Carotid endarterectomy - the evidence. *Journal of the Royal Society of Medicine*. 2002;95(4):168-170.
4. European Carotid Surgery Trialists Collaborative Group. Randomised trial of endarterectomy for recently symptomatic carotid stenosis: final results of the MRC European Carotid Surgery Trial (ECST). *Lancet*. 1998;351: 1379-87.
5. Benavente O, Moher D, Pham B. Carotid endarterectomy for asymptomatic carotid stenosis: a meta-analysis. *BMJ*. 1998;317:1477-80.
6. Palerme LP, Hill AB, Obrand D, Steinmetz OK. Is Canadian surgeons' management of asymptomatic carotid artery stenosis at coronary artery bypass supported by the literature? A survey and a critical appraisal of the literature. *Can J Surg*. 2000;43:93-113.
7. Friedman SG. The first carotid endarterectomy. *Journal of Vascular Surgery*. 2014;60(6):1703-8.
8. Eastcott HH, Pickering GW, Rob CG. Reconstruction of internal carotid artery in a patient with intermittent attacks of hemiplegia. *Lancet*. 1954;267(6846):994-6.
9. Earnshaw JJ. The endovascular revolution. *Ann R Coll Surg Engl*. 1997;79:81-2.
10. Findlay JM, Marchak BE, Pelz DM, Feasby TE. Carotid endarterectomy: a review. *Can J Neurol Sci*. 2004;31(1):22-36.
11. Ricotta JJ, Aburahma A, Ascher E, Eskandari M, Faries P, Lal BK, et al. Updated Society for Vascular Surgery guidelines for management of extracranial carotid disease. *J Vasc Surg*. 2011;54(3):e1-31.
12. Beneficial effect of carotid endarterectomy in symptomatic patients with high-grade carotid stenosis. North American Symptomatic Carotid Endarterectomy Trial Collaborators. *N Engl J Med*. 1991;325(7):445-53.
13. Endarterectomy for asymptomatic carotid artery stenosis. Executive Committee for the Asymptomatic Carotid Atherosclerosis Study. *JAMA*. 1995;273(18):1421-8.
14. Kernan WN, Ovbiagele B, Black HR, et al, American Heart Association Stroke Council, Council on Cardiovascular and Stroke Nursing, et al. Guidelines for the prevention of stroke in patients with stroke and transient ischemic attack: a guideline

- for healthcare professionals from the American Heart Association/American Stroke Association. *Stroke*. 2014;45(7):2160-236.
15. Salem MK, Sayers RD, Bown MJ, Eveson DJ, Robinson TG, Naylor AR. Rapid access carotid endarterectomy can be performed in the hyperacute period without a significant increase in procedural risks. *Eur J Vasc Endovasc Surg*. 2011;41(2):222-8.
 16. Cooper M, Arhuidese IJ, Obeid T, Hicks CW, Canner J, Malas MB. Perioperative and Long-term Outcomes After Carotid Endarterectomy in Hemodialysis Patients. *JAMA Surg*. 2016;151(10):947-952.
 17. Bruls S, Van Damme H, Defraigne JO. Timing of carotid endarterectomy: a comprehensive review. *Acta Chir Belq*. 2012;112(1):3-7.
 18. Landis GS, Faries PL. A critical look at “high-risk” in choosing the proper intervention for patients with carotid bifurcation disease. *Semin Vasc Surg*. 2007;20:199–204.
 19. Caplan LR, Skillman J, Ojemann R, Fields WS. Intracerebral hemorrhage following carotid endarterectomy: a hypertensive complication? *Stroke*. 1978;9:457–460.
 20. Giordano JM, Trout HH, 3rd, Kozloff L, DePalma RG. Timing of carotid artery endarterectomy after stroke. *J Vasc Surg*. 1985;2:250–255.
 21. Gasecki AP, Ferguson GG, Eliasziw M, Clagett GP, Fox AJ, Hachinski V, Barnett HJ. Early endarterectomy for severe carotid artery stenosis after a nondisabling stroke: results from the North American Symptomatic Carotid Endarterectomy Trial. *J Vasc Surg*. 1994;20:288–295.
 22. Beneficial effect of carotid endarterectomy in symptomatic patients with high-grade carotid stenosis. North American Symptomatic Carotid Endarterectomy Trial Collaborators. *N Engl J Med*. 1991;325:445–453.
 23. Nehler MR, Moneta GL, McConnell DB, Edwards JM, Taylor LM, Jr., Yeager RA, Porter JM. Anticoagulation followed by elective carotid surgery in patients with repetitive transient ischemic attacks and high-grade carotid stenosis. *Arch Surg*. 1993;128:1117–1121; discussion 1121–1123.
 24. Inzitari D, Eliasziw M, Gates P, Sharpe BL, Chan RK, Meldrum HE, Barnett HJ. The causes and risk of stroke in patients with asymptomatic internal-carotid-artery stenosis. North American Symptomatic Carotid Endarterectomy Trial Collaborators. *N Engl J Med*. 2000;342:1693–1700.
 25. Eckstein HH, Schumacher H, Dorfler A, Forsting M, Jansen O, Ringleb P, Allenberg JR. Carotid endarterectomy and intracranial thrombolysis: simultaneous and staged procedures in ischemic stroke. *J Vasc Surg*. 1999;29:459–471.
 26. Deriu GP, Milite D, Damiani M, *et al*. Carotid endarterectomy without angiography: a prospective randomised pilot study. *Eur J Vasc Endovasc Surg*. 2000;20:250-3

27. Johnson DCC, Goldstein LB. Clinical carotid endarterectomy decision making: non-invasive vascular imaging versus angiography. *Neurology*. 2001;56:1009-15.
28. Cao P, Giordano G, De Rango P, *et al*. Eversion versus conventional carotid endarterectomy: late results of a prospective multicenter randomised trial. *J Vasc Surg*. 2000;31:19-30.
29. Counsell C, Salinas R, Warlow C, Naylor R. Patch angioplasty versus primary closure for carotid endarterectomy. *Cochrane Database Syst Rev*. 2000:CD000160.
30. Ballotta E, Da Giau, Saladini M, Abbruzzese E, Renon L, Toniato A. Carotid endarterectomy with patch closure versus carotid eversion endarterectomy with reimplantation: a prospective randomised study. *J Vasc Surg*. 1999;125:271-9.
31. Al-Rawi PG, Turner CL, Waran V, Ng I, Kirkpatrick PJ. A randomized trial of synthetic patch versus direct primary closure in carotid endarterectomy. *Neurosurgery*. 2006;59:822–828; discussion 828–829.
32. Bond R, Rerkasem K, Naylor R, Rothwell PM. Patches of different types for carotid patch angioplasty. *Cochrane Database Syst Rev*. 2004:CD000071.
33. Yamamoto Y, Piepgras DG, Marsh WR, Meyer FB. Complications resulting from saphenous vein patch graft after carotid endarterectomy. *Neurosurgery*. 1996;39:670-675; discussion 675–676.
34. CAVATAS investigators. Endovascular *versus* surgical treatment in patients with carotid stenosis in the Carotid and Vertebral Artery Transluminal Angioplasty Study (CAVATAS): a randomised trial. *Lancet*. 2001;357:1729-37.
35. Naylor AR, Bolia A, Abbott RJ, *et al*. Randomised study of carotid angioplasty and stenting *versus* carotid endarterectomy: a stopped trial. *J Vasc Surg*. 1998;28:326-34.
36. Kresowik TF, Bratzler DW, Kresowik RA, Hendel ME, Grund SL, Brown KR, Nilasena DS. Multistate improvement in process and outcomes of carotid endarterectomy. *J Vasc Surg*. 2004;39:372–380.